

MR DAVID CHEUNG

Consultant Ophthalmic and Oculoplastic Surgeon

Contact Info

NHS: Sandwell General Hospital, Birmingham PA: Denise Kaur 0121 507 3165
Russells Hall Hospital, Dudley : PA Jo Gough: 01384 244811

Private Patients: The Edgbaston Hospital, Birmingham: General 0121 456 2000, Appointments 0121 452 2810
West Midlands Hospital, Halesowen: General 01384 560123, Appointments 01384 880174
PA Liz Carter 01384 632636

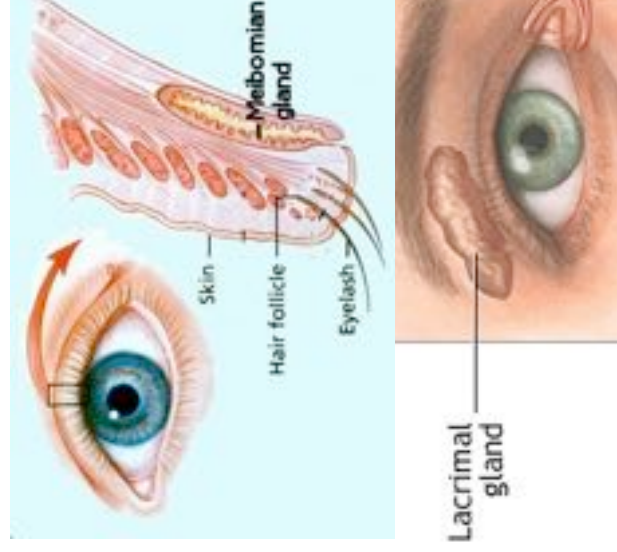
Website: www.mrdavidcheung.com

Meibomian Gland Dysfunction and Chalazia

We hope this information will help answer any questions you may have regarding meibomian gland dysfunction and chalazia. This information sheet is for your general information only and is not intended to be a substitute for a proper consultation by a trained medical professional. For further information, please feel free to look at Mr Cheung's professional website www.mrdavidcheung.com. Although several commercial products are mentioned in this patient handout, Mr Cheung has no financial interest in any of them.

What are the meibomian glands and what do they do?

- The normal eyelid is made of muscle and skin on the front and a rigid cartilage-like structure on the back. This cartilage-like structure gives the eyelid its rigidity and is known as the tarsal plate. Located within the tarsal plate are the meibomian glands- 20-30 tiny specialised oil glands which secrete a fine film of oil on to the surface of the eye. If one carefully looks at the edge of the eyelid, one can see tiny holes which represent the openings of the ducts through which the meibomian glands secrete their oil.
- This oil which is known as **mebum** has an important job in contributing to the tear film on the surface of the eye. The normal tear film of the eye is largely made of a watery secretion (from the lacrimal gland which lies behind the upper eyelid) and mebum (from the meibomian glands of the eyelids). These two components work together to form an emulsion which then lubricates the surface of the eye.

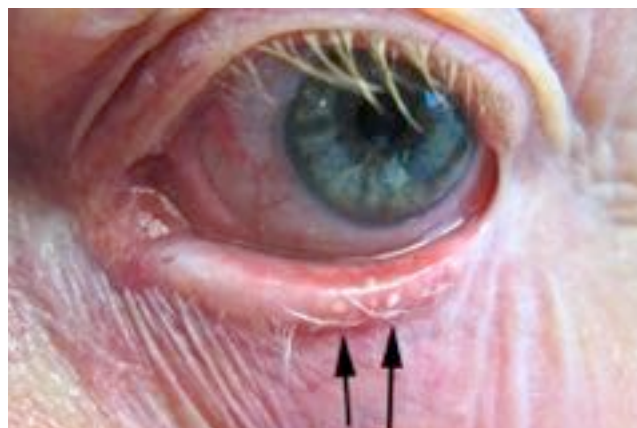


- The mebum enhances the ability of the tear film to stick to surface of the eye- that is it increases the wetting ability of the tear film. In the same way that it is difficult to paint a wall with a simple water based paint which just drips off the wall, so it is the same with the eye's tear film. If it was not for the presence of the mebum within the tear film, the tears would just drip off the eye surface leading to poor surface lubrication. In much the same way that a windshield wiper can drag against a dry windshield, so too can the eyelids drag and irritate the eye surface if it not were for the presence of this lubricating tear film emulsion.

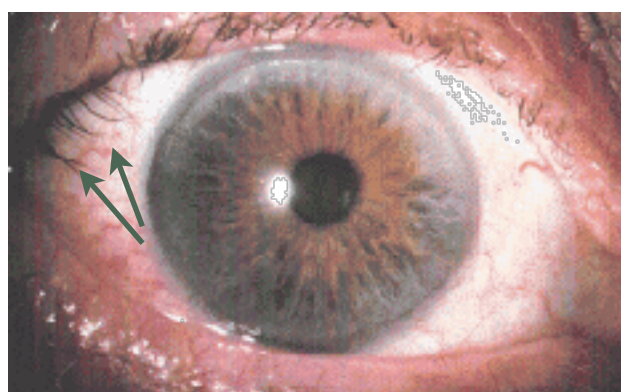
What is Meibomian Gland Dysfunction and how does it affect me?

- Meibomian Gland Dysfunction (MGD) is essentially when the meibomian glands are no longer working properly i.e. they've gone on strike!
- They no longer produce the fine light oil and instead often produce a thick sticky butter-like fatty substance instead.
- This thick turgid secretion can cause several problems:

1. It no longer has the same stabilising effect of normal mebum leading to a poor quality tear film that lubricates the eye surface poorly. The eye can feel sore and irritable as a result. In some patients the eye becomes intermittently red and watery, particularly in dry environments where the tear film tends to evaporate even quicker e.g. outdoors, in air conditioned warm rooms/cars . Although the patient may be producing a large quantity of tears, the tear film *quality* is poor- the tears tend to evaporate too quickly and are poor at actually wetting the surface of the eye. Oddly, the situation is known as **evaporative dry eye**. The patient often complains of scratchy, burning, gritty eyes which are worsened by dry environments. They can also complain of increased watering usually outdoors (known as reflex hyperlacrimation) and strangely dry eye drops can improve their watering eye symptoms by improving patient comfort.
2. It can clog up the ducts of the meibomian glands causing them to obstruct. This can lead to **chalazion** formation (see below)
3. In severe forms of meibomian gland dysfunction, the edge of the eyelid can become very inflamed (known as blepharitis). Various types of blepharitis exist but they can all lead to localised scarring along the edge of eyelid which can result in migration of the eyelash bearing skin inwards so that the eyelashes point inwards towards the eye (entropion). Sometimes the eyelashes actually touch the eye surface causing irritation (trichiasis).



Note the sticky thick white butter like mebum emerging from the meibomian glands in this patient with MGD



Due to chronic inflammation of this patient's meibomian glands, the edge of the eyelid has become scarred causing the eyelashes to turn inwards to touch the eye surface.

How do I improve my MGD?

Since the actual cause of MGD is unknown, there are currently no cures for the disease. There are various theories as to the cause of MGD (including overgrowth of bacteria which colonise the oil glands, abnormal oil production, dietary influences, etc) but no conclusive cause has ever been found.

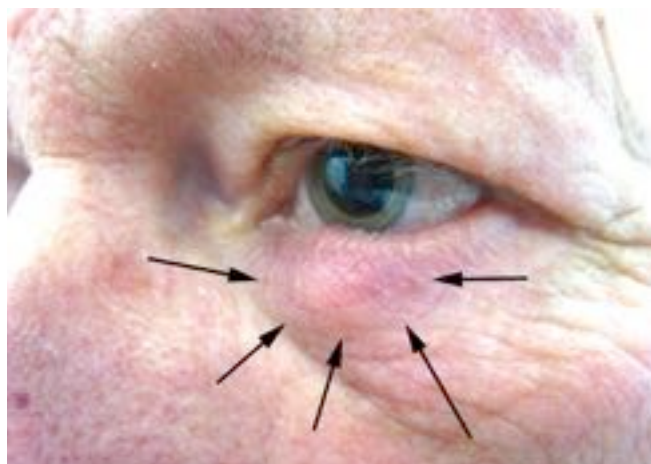
However there are lots of treatments which can improve patient symptoms:

- **Hot compresses:** Hot compresses improve patient symptoms by unblocking the clogged up meibomian glands, over time improving the quality of the mebum and its ability to stabilise the tear film. By practising hot compresses to the eyelids, chalazia often self resolve, the patient's tear film quality improves leading to less irritation and possibly less watering. Traditionally patients are often advised about using a hot face flannel to the eyelids and hot spoon bathing. More recently various devices have been available including microwaveable heat retaining bean bags or hempseed bags (www.eyebagcompany.com) which offer convenience to the patient. Regardless of whatever method the patient uses to warm the eyelid - hot compresses only work well if one practises it regularly. It is also important to remember that in addition the local warmth to the eyelids which essentially melts the thick buttery mebum, local massage to the eyelid is necessary to encourage the meibomian glands to empty, thus improving mebum quality.
- **Ocular lubricants:** Ocular lubricants can greatly improve patient's symptoms. They do not cure MGD but do offer patient comfort and often reduce watering by making the patient's eyes more comfortable. Drops such as **Hylforte** and the newer generation of drops such as **Systane Balance** and **Optive Plus** can be very beneficial to patient symptoms. There are many different types of drops and often the best drop is one of personal preference meaning that one may have to try several to find one that suits. They can be all be used frequently and many patients find that they have to use their drops 6-8 times a day. Many of these drops are available over the counter without the need for a GP prescription.

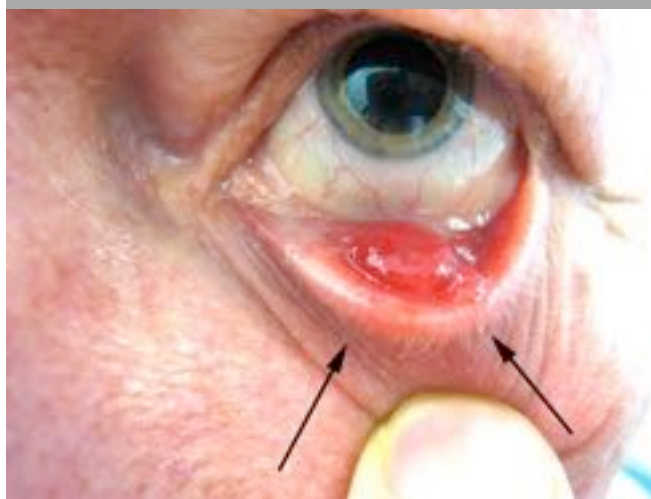- **Oral antibiotics:** For some patients who have particularly severe MGD, their ophthalmologist may prescribe antibiotic tablets such as doxycycline. These are thought to act by interfering with the production of oil by the meibomian glands. They are commonly prescribed in conditions such as rosacea and acne- more generalised skin conditions associated with disturbance of oil gland secretion and work in a similar fashion.
- **Omega-3 supplements:** there is emerging evidence that a diet high in Omega-3 (as in some oily fish and Omega-3 dietary supplements) can improve MGD in the long run. Specifically formulated preparations include **Omega Eye** which can be ordered directly from Scope Ophthalmics (www.scopeomegahealth.com).

Chalazia

- Occasionally the abnormally thick mebum may clog up the ducts of the meibomian glands causing them to obstruct. The mebum builds up within the glands, which then start to swell and inflame resulting in redness and pain. The inflammation usually self resolves within a couple of weeks.
- The correct term for one of these lumps is a **chalazion** (plural= **Chalazia**).
- Sometimes they are incorrectly called **styes** -which are actually blockages of oil glands associated with the eyelash and not the meibomian glands of the tarsal plate.
- A old local Black Country term for chalazia and styes is "powks".
- The term "cyst" refers to any lesion fluid filled lesion. The most common type of eyelid cyst is a chalazion, but many different types of eyelid cyst exist.
- Although incorrect, even doctors use these terms interchangeably.
- For the vast majority of patients, chalazia self resolve and 95% of them will self-resolve within two years.
 - These chalazia may self-resolve by rupturing through the skin on the front of the eyelid or through the back of the eyelid.
 - Most favourably for the patient, the duct of the affected meibomian gland itself may unblock, allowing the retained mebum to discharge. Mr Cheung therefore recommends regular hot compresses to encourage this most favourable outcome.
- A small minority of chalazia persist. They may occasionally inflame, cause a cosmetic nuisance, interfere with the function of eyelid and rarely become so large as to distort vision. Their removal is occasionally recommended with an operation known as an *incision and curettage*. This is quick operation usually performed under local anaesthetic as a day case procedure and essentially involves making a small incision (usually through the back surface of the eyelid) over the chalazion and scraping out (curetting) its contents. An eye patch is worn usually for 3-4 hours and antibiotic ointment is administered to the eye for usually 3-4 days afterwards. The patient's tears are usually pink for the first few days as the incision heals and the back of the eyelid is temporarily sore. Rarely chalazia recur even after surgery and further surgery may be recommended.
- **If a chalazion recurs in the same place despite surgery**, Mr Cheung may recommend biopsy of the tarsal plate of the eyelid to ensure correct diagnosis and rule out other more sinister causes of eyelid lumps.



A Chalazion



Sources of further information

Various websites of interest include:

- www.dryeyezone.com
- www.eyebagcompany.com
- www.eyecareeducators.com/site/pearls_blepharitis_treatment_protocol.htm